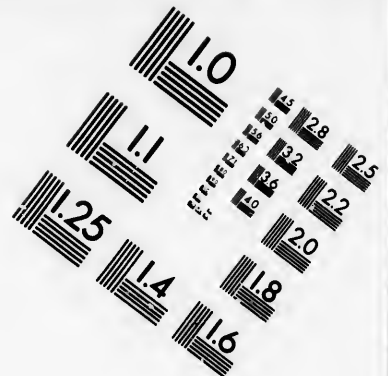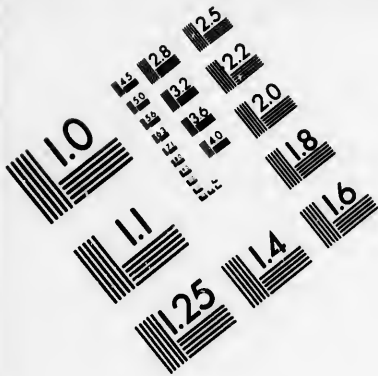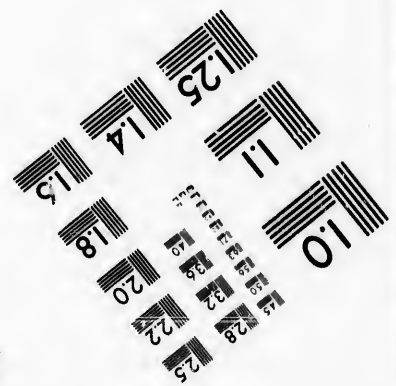
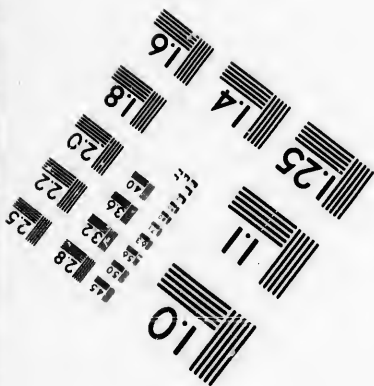




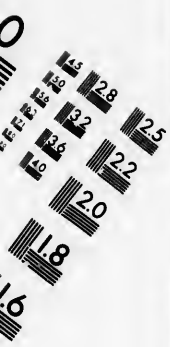**IMAGE EVALUATION
TEST TARGET (MT-3)**



**Photographic
Sciences
Corporation**

23 WEST MAIN STREET
WEBSTER, N.Y. 14580
(716) 872-4503



**CIHM/ICMH
Microfiche
Series.**

**CIHM/ICMH
Collection de
microfiches.**



Canadian Institute for Historical Microreproductions / Institut canadien de microreproductions historiques



© 1986

Technical and Bibliographic Notes/Notes techniques et bibliographiques

The Institute has attempted to obtain the best original copy available for filming. Features of this copy which may be bibliographically unique, which may alter any of the images in the reproduction, or which may significantly change the usual method of filming, are checked below.

L'Institut a microfilmé le meilleur exemplaire qu'il lui a été possible de se procurer. Les détails de cet exemplaire qui sont peut-être uniques du point de vue bibliographique, qui peuvent modifier une image reproduite, ou qui peuvent exiger une modification dans la méthode normale de filmage sont indiqués ci-dessous.

- | | |
|--|--|
| <input checked="" type="checkbox"/> Coloured covers/
Couverture de couleur | <input type="checkbox"/> Coloured pages/
Pages de couleur |
| <input type="checkbox"/> Covers damaged/
Couverture endommagée | <input type="checkbox"/> Pages damaged/
Pages endommagées |
| <input type="checkbox"/> Covers restored and/or laminated/
Couverture restaurée et/ou pelliculée | <input type="checkbox"/> Pages restored and/or laminated/
Pages restaurées et/ou pelliculées |
| <input type="checkbox"/> Cover title missing/
Le titre de couverture manque | <input checked="" type="checkbox"/> Pages discoloured, stained or foxed/
Pages décolorées, tachetées ou piquées |
| <input type="checkbox"/> Coloured maps/
Cartes géographiques en couleur | <input type="checkbox"/> Pages detached/
Pages détachées |
| <input type="checkbox"/> Coloured ink (i.e. other than blue or black)/
Encre de couleur (i.e. autre que bleue ou noire) | <input checked="" type="checkbox"/> Showthrough/
Transparence |
| <input type="checkbox"/> Coloured plates and/or illustrations/
Planches et/ou illustrations en couleur | <input type="checkbox"/> Quality of print varies/
Qualité inégale de l'impression |
| <input checked="" type="checkbox"/> Bound with other material/
Relié avec d'autres documents | <input type="checkbox"/> Includes supplementary material/
Comprend du matériel supplémentaire |
| <input type="checkbox"/> Tight binding may cause shadows or distortion
along interior margin/
La reliure serrée peut causer de l'ombre ou de la
distorsion le long de la marge intérieure | <input type="checkbox"/> Only edition available/
Seule édition disponible |
| <input type="checkbox"/> Blank leaves added during restoration may
appear within the text. Whenever possible, these
have been omitted from filming/
Il se peut que certaines pages blanches ajoutées
lors d'une restauration apparaissent dans le texte,
mais, lorsque cela était possible, ces pages n'ont
pas été filmées. | <input type="checkbox"/> Pages wholly or partially obscured by errata
slips, tissues, etc., have been refilmed to
ensure the best possible image/
Les pages totalement ou partiellement
obscurcies par un feuillet d'errata, une pelure,
etc., ont été filmées à nouveau de façon à
obtenir la meilleure image possible. |
| <input type="checkbox"/> Additional comments:/
Commentaires supplémentaires: | |

This item is filmed at the reduction ratio checked below/
Ce document est filmé au taux de réduction indiqué ci-dessous.

10X	14X	18X	22X	26X	30X
<input type="checkbox"/>	<input type="checkbox"/>	<input type="checkbox"/>	<input checked="" type="checkbox"/>	<input type="checkbox"/>	<input type="checkbox"/>
12X	16X	20X	24X	28X	32X

The copy filmed here has been reproduced thanks to the generosity of:

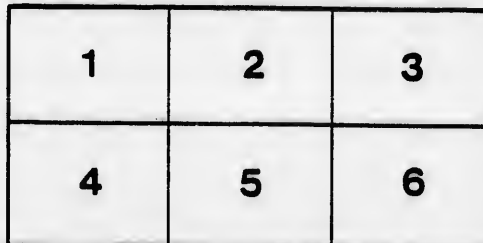


Medical Library
McGill University
Montreal

The images appearing here are the best quality possible considering the condition and legibility of the original copy and in keeping with the filming contract specifications.

Original copies in printed paper covers are filmed beginning with the front cover and ending on the last page with a printed or illustrated impression, or the back cover when appropriate. All other original copies are filmed beginning on the first page with a printed or illustrated impression, and ending on the last page with a printed or illustrated impression.

The last recorded frame on each microfiche shall contain the symbol \rightarrow (meaning "CONTINUED"), or the symbol ∇ (meaning "END"), whichever applies.

Maps, plates, charts, etc., may be filmed at different reduction ratios. Those too large to be entirely included in one exposure are filmed beginning in the upper left hand corner, left to right and top to bottom, as many frames as required. The following diagrams illustrate the method:



L'exemplaire filmé fut reproduit grâce à la générosité de:

Medical Library
McGill University
Montreal

Les images suivantes ont été reproduites avec le plus grand soin, compte tenu de la condition et de la netteté de l'exemplaire filmé, et en conformité avec les conditions du contrat de filmage.

Les exemplaires originaux dont la couverture en papier est imprimée sont filmés en commençant par le premier plat et en terminant soit par la dernière page qui comporte une empreinte d'impression ou d'illustration, soit par le second plat, selon le cas. Tous les autres exemplaires originaux sont filmés en commençant par la première page qui comporte une empreinte d'impression ou d'illustration et en terminant par la dernière page qui comporte une telle empreinte.


Un des symboles suivants apparaîtra sur la dernière image de chaque microfiche, selon le cas: le symbole \rightarrow signifie "A SUIVRE", le symbole ∇ signifie "FIN".

Les cartes, planches, tableaux, etc., peuvent être filmés à des taux de réduction différents. Lorsque le document est trop grand pour être reproduit en un seul cliché, il est filmé à partir de l'angle supérieur gauche, de gauche à droite, et de haut en bas, en prenant le nombre d'images nécessaire. Les diagrammes suivants illustrent la méthode.

errata
to

pelure,
on à

32X



61

*Umbilical Faecal Fistula in an Infant
Cured by Radical Operation.*

(ILLUSTRATED)

By FRANCIS J. SHEPHERD, M D., C.M.,

Professor of Anatomy and Lecturer on Operative Surgery in McGill University;
Surgeon to the Montreal General Hospital.

REPRINTED FROM
THE ARCHIVES OF PEDIATRICS,
JANUARY, 1892.

UMBILICAL FÆCAL FISTULA IN AN INFANT CURED BY RADICAL OPERATION.

(ILLUSTRATED.)

By FRANCIS J. SHEPHERD, M.D., C.M.,

Professor of Anatomy and Lecturer on Operative Surgery in McGill University ;
Surgeon to the Montreal General Hospital.*

CASES of umbilical fæcal fistula in infants are comparatively rare, and when they occur are caused by the inclusion of prolapsed intestine in the ligature used to tie the cord. This intestine may be a herniated portion of small bowel, or, as is most commonly the case, a persistent omphalo-mesenteric duct extending down into the cord. This duct not infrequently persists as a diverticulum from the ileum, ten to sixty inches from the ileo-cæcal valve. It is then called Meckel's diverticulum, and is usually two to three inches long, and of about the same diameter as the bowel. It occurs in about two per cent. of individuals, and chiefly in males. In some rare cases it is connected with the umbilicus by a cord which represents the obliterated duct, and is one of the causes of internal strangulation of the bowel. In still rarer cases the duct is patent not only as far as the umbilicus, but even some distance down the cord. In such cases when the cord is ligatured at birth the duct is included in the ligature, and as the ligature ulcerates through and separates, it cuts through the duct, and hence a fæcal fistula is the result. Now the cure of these fistulæ has always been difficult and unsatisfactory. Holmes asserts that as far as he has seen they are incurable, and Mr. Owen "Surgical Diseases of Children," says no plastic operation or cauterization is apt to succeed, but asserts that he has cured two cases by cleaning out the contents of the bowels with rhubarb and soda, and then keeping the bowels at rest for a fortnight with

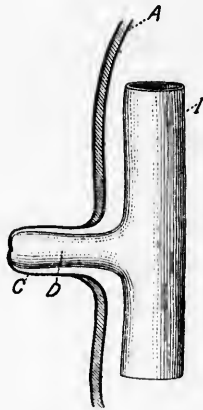
* Read before the Montreal Medico-Chirurgical Society, November 20, 1891.

opium in small doses. At the same time the fistula is covered by a thick dressing of vaseline and eucalyptus. It seems to me that only very small fæcal fistula could be cured by these means, and that the more scientific procedure is the one I adopted with success in the following case:

CASE.—Arthur B., of Moosejaw, N. W. T., aged three months, a strong, healthy, well-nourished infant, was admitted into the Montreal General Hospital, September 18, 1891, suffering from a fæcal fistula at the umbilicus. At birth nothing seemed amiss with the cord except that it was thicker than usual. The ligature came away on the fifth day, and the nurse noticed that flatus was escaping from the navel next day. Later fæces appeared, and have been discharging in larger or smaller quantities ever since. After the ligature separated, Dr. Turnbull, under whose care the case was, writes me that the stump of the cord appeared much as in other cases, but in a few days began to protrude or grow outward.

The condition of the umbilicus on entrance into hospital was as follows: "At the site of the umbilicus a protrusion, which is in size and appearance like a child's penis; it is one and a half inches long, with an opening at the extremity looking much like the preputial orifice. The outer surface of the protruded portion is red and vascular, bleeds easily on handling, and very much resembles mucous membrane. There is an areola some three or four inches in diameter around the umbilicus, which is in a raw, red, eczematous condition, owing to the parts being kept continually moist by the constant discharge from the end of the protrusion. On introducing a probe, it enters freely for some distance, and on withdrawing it some yellow feces escape. The fistula is easily dilatable, and a pair of Péan's artery forceps can be passed in with ease." Now as to the nature of the protrusion: it was either a portion of prolapsed intestine everted so that the mucous membrane was external, or it was the stump of the cord denuded of epithelium and in an eczematous condition.

The child was shown at the Meeting of the Canadian Medical Association, which happened to be meeting in Montreal at the time, and among others it was seen by Mr. Bryant, of London. The general opinion was that the protrusion was due to everted mucous membrane probably from a persistent vitelline duct. That the fistula was connected with a Meckel's diverticulum was probable, for the excellent condition of the child led me to the conclusion that the fistula was either connected with the large bowel or the lower end of the small intestines.



A, Abdominal wall; *C*, Stump of cord containing (*D*) diverticulum from (*I*) ileum.

Operation for radical cure having been determined on, the patient was put under chloroform on September 19th. An incision was first made through the protrusion, near to its exit from the abdomen. This incision revealed the fact that it was not mucous membrane, but skin deprived of epithelium; for, on cutting it through, the peritoneal cavity was entered and a portion of bowel seen to be protruding through an opening at the umbilicus; this bowel, by its open extremity, was continuous with the fistula already described. It was now determined to enlarge the incision by opening up the abdominal cavity above the

umbilicus, and to examine further. This was done, and the protruded portion of the bowel was drawn out and found to be a diverticulum from the small intestines. The diverticulum was cut off close to where it was given off from the gut, and the opening thus left sutured by a double row of continuous silk sutures, the outer row of which included only the peritoneal coat of the bowel. The sutured bowel, after having been found perfectly water-tight, was dropped back into the abdomen, the stump of the cord cut off and the abdominal wound closed with three silkworm-gut sutures. The wound was dusted over with iodoform, covered with absorbent cotton, kept in place by adhesive plaster. The child's condition after operation was excellent. For twenty-four hours it was given no food, and then was allowed to have the breast for a few minutes at a time every two hours. Having to leave town, Dr. James Bell kindly looked after the case for me. The stitches were removed on the sixth day, and the wound was found to be perfectly healed. The child's condition continued good, and he left the hospital on the 25th of September, and went home to the Northwest as well as ever on the 30th. I have since had a letter from Dr. Turnbull, dated November 18, 1891. He writes that the child is in the best of health and growing rapidly.

nd
nd
ne
off
a
of
el.
ly
ne
ed
ed
pt
er
as
st
to
or
id
's
ne
as
n
at

